

CASE REPORT

Richter's hernia following operative laparoscopy

Ashwini Kumar Trehan

Accepted for publication 15 July 1996

Summary

A case of Richter's hernia following laparoscopic-assisted vaginal hysterectomy (LAVH) is presented.

Keywords: complication, laparoscopic surgery, LAVH, Richter's hernia.

Case report

An obese 50-year-old lady underwent laparoscopic-assisted vaginal hysterectomy and laparoscopic bilateral salpingo-oophorectomy using our routine three-port technique (a subumbilical 10-mm port and two 12-mm lateral ports). The postoperative period was uneventful.

On the 12th postoperative day the patient left the UK on a business trip to France. She returned three days later with vomiting once every night, mild diarrhoea and some colicky pain. The abdomen was soft and there was no tenderness of trocar site. She was admitted to hospital on the 18th postoperative day with suspected small bowel obstruction, as X-rays suggested mild distension of small bowel and fluid level.

A laparotomy was performed on the 20th postoperative day. A Richter's type hernia, involving part of the wall of the small bowel, was found between the peritoneal covering and sheath of the lateral abdominal wall at the site of a 12-mm port (Fig. 1). The hernia was released by simply pulling the bowel out of the hernia sac at laparotomy. The peritoneal defect was closed with one stitch. Following this, recovery was complete.

Discussion

Richter's hernia is a condition where a part of the circumference of the intestine herniates. The condition usually occurs in relation to femoral hernia or occasionally with an obturator hernia. Recently the condition has been increasingly reported in relation to laparoscopic operative surgery where 10-mm or larger size ports are used.

There is usually a delay in recognition of Richter's hernia as the passage of contents through the bowel

continues until paralytic ileus supervenes. The condition may mimic gastroenteritis. The patient may not vomit or may vomit only once or twice a day. Intestinal colic occurs but the bowels are either opened normally or there may be diarrhoea.

This patient presented on postoperative day 18 with vomiting once a day, mild diarrhoea and some colicky abdominal pain. Initially an allergic reaction to an antibiotic prescribed for vaginal discharge was suspected; there was no abdominal distension. However, X-ray of the abdomen showed mild dilatation of the upper intestine and some fluid levels, leading to a diagnosis of subacute obstruction.

In cases of Richter's hernia the partial enterocele usually undergoes strangulation, resulting in gangrene of the knuckle of the bowel, as the tight neck of the hernia leads to obliteration of the blood supply. In this case gangrene did not occur as the neck of the herniated circumference of the bowel was a thin layer of peritoneum and easily extended, rather than being non-stretchable fascia.

A review of the literature¹⁻⁷ suggests that all the incisional hernia that have been reported after diagnostic laparoscopy occurred when an 11- or 12-mm subumbilical trocar was used. The incidence was low, having a range of one in 5000 to one in 10,000.^{1,2,8} Most hernias contained omentum rather than bowel.

With the exception of one patient who had an incarcerated hernia that was reported a year after surgery, the five cases of incisional hernia reported by Nicholas Kadar *et al.* appeared within the first 10 days after surgery.⁹ In our patient hernia signs and symptoms were delayed for 18-20 days.

The above mentioned 1993 publication by Kadar *et al.* suggests a high incidence of hernia associated with operative laparoscopy: one in 429 (0.23%) and five in 161 (3.1%) at 10- and 12-mm extraumbilical trocar insertion sites, respectively. These authors have concluded that underlying fascia should be closed whenever a 10-mm or larger trocar is placed at an extraumbilical site during laparoscopy. They have further suggested that peritoneum may only require closure at 12-mm sites if the trocar is placed through, rather than lateral to the rectus sheath.

In the case reported here, the trocar had been placed lateral to the rectus sheath and the

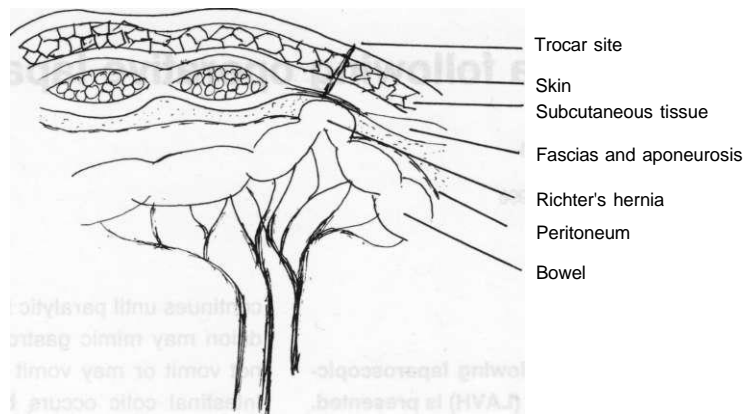


Figure 1 Richter's hernia at the site of insertion of a 12-mm lateral port.

circumference of the bowel had herniated through the peritoneum and was lying beneath the fascia.

Precautionary measures for avoiding hernias at trocar sites include: full-thickness closure of the trocar site, with a specially designed needle such as a 'J'-shaped needle¹⁰, or Semm's emergency needle;¹¹ creating a 'Z' track in the abdominal wall;³ deflating the abdomen before removing the sheath occluded by a solid instrument, or lifting and shaking the abdominal wall at removal of the instruments.¹²

I suggest that the peritoneum should always be closed at extraumbilical 12-mm trocar sites whether the trocar is placed through or lateral to the rectus sheath, and this is now our routine practice.

One should always consider the diagnosis of incisional hernia, following operative laparoscopy, if a recovering patient suddenly shows signs of gastroenteritis that does not respond quickly to conservative treatment.

References

- Mintz M. Risks and prophylaxis in laparoscopy: a survey of 100000 cases. *Journal of Reproductive Medicine* 1977; **18**: 269-72.
- Cunannan RG, Courey NG, Lippes J. Complications of laparoscopic tubal sterilisation. *Obstetrics and Gynecology* 1987; **66**: 735-6.
- Bishops HL, Halpin TF. Dehiscence following laparoscopy: report of an unusual complication. *American Journal of Obstetrics and Gynaecology* 1973; **116**: 585-6.
- Schiff I, Nattolin F. Small bowel incarceration after uncomplicated laparoscopy. *Obstetrics and Gynaecology* 1974; **43**: 674-5.
- Bourke JB. Small intestinal obstruction from a Richter's hernia at the site of insertion of a laparoscope. *British Medical Journal* 1977; **2**: 1393-4.
- Sauer M, Jarette JC. Small bowel obstruction following diagnostic laparoscopy. *Fertility and Sterility* 1984; **42**: 653-4.
- Hogdall C, Roosen JU. Incarcerated hernia following laparoscopy. *Acta Obstetrica et Gynecologica Scandinavica* 1987; **66**: 735-6.
- Loffer DF, Pent D. Indications, contraindications, and complications of laparoscopy. *Obstetrics and Gynecology* 1975; **30**: 407-27.
- Kadar N, Reich H, Liu CY, Manko GF, Gimpelson R. Incisional hernias after major laparoscopic gynecological procedures. *American Journal of Obstetrics and Gynecology* 1993; **168**: 1493-5.
- Phipps JH. Full thickness closure of laparoscopic port sites: a device for prevention of hernias and management of abdominal wall vessel injury. *Journal of Gynaecologic Techniques* 1995; **1**: 51-4.
- Lueken RP, Gallinat TA, Moller CP, Busche D, Nugent W. A new technique of peritoneal closure after laparoscopic surgery. *Gynaecological Endoscopy* 1995; **4**: 145-6.
- Kiholma P, Makinen J. Incarcerated Richter's hernia after laparoscopy: a case report. *European Journal of Obstetrics Gynaecology and Reproductive Biology* 1988 **28**: 75-7.